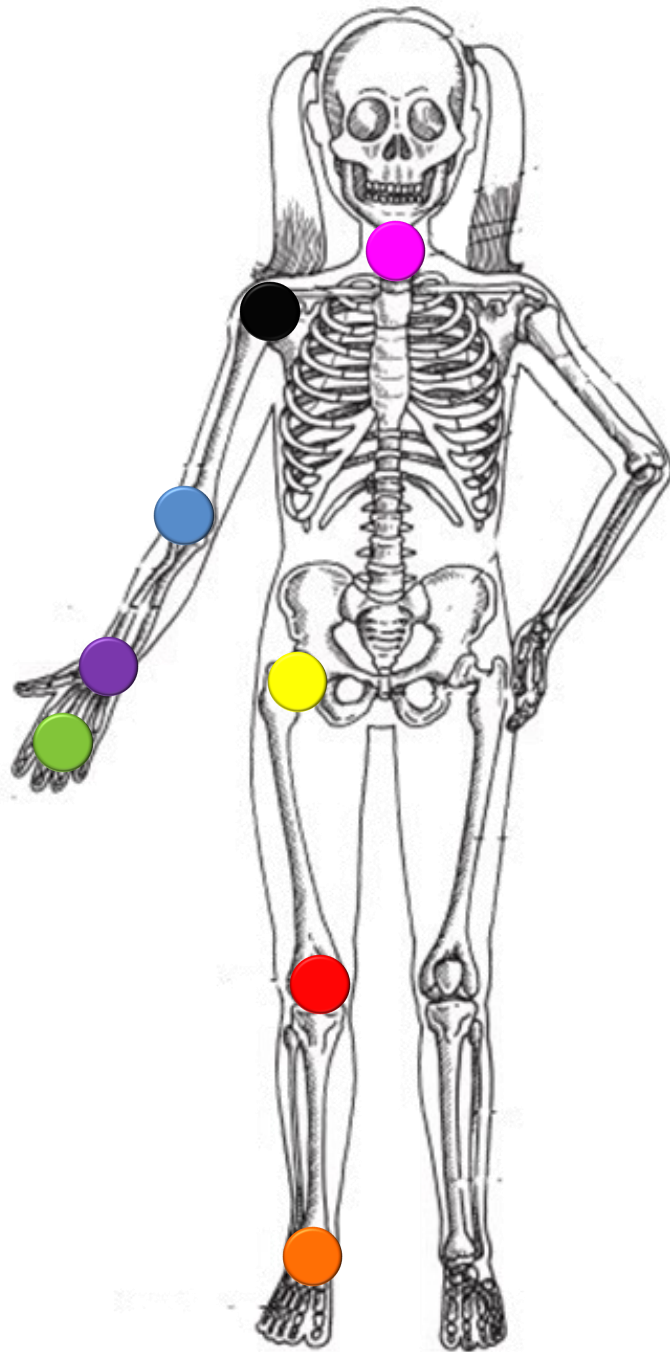



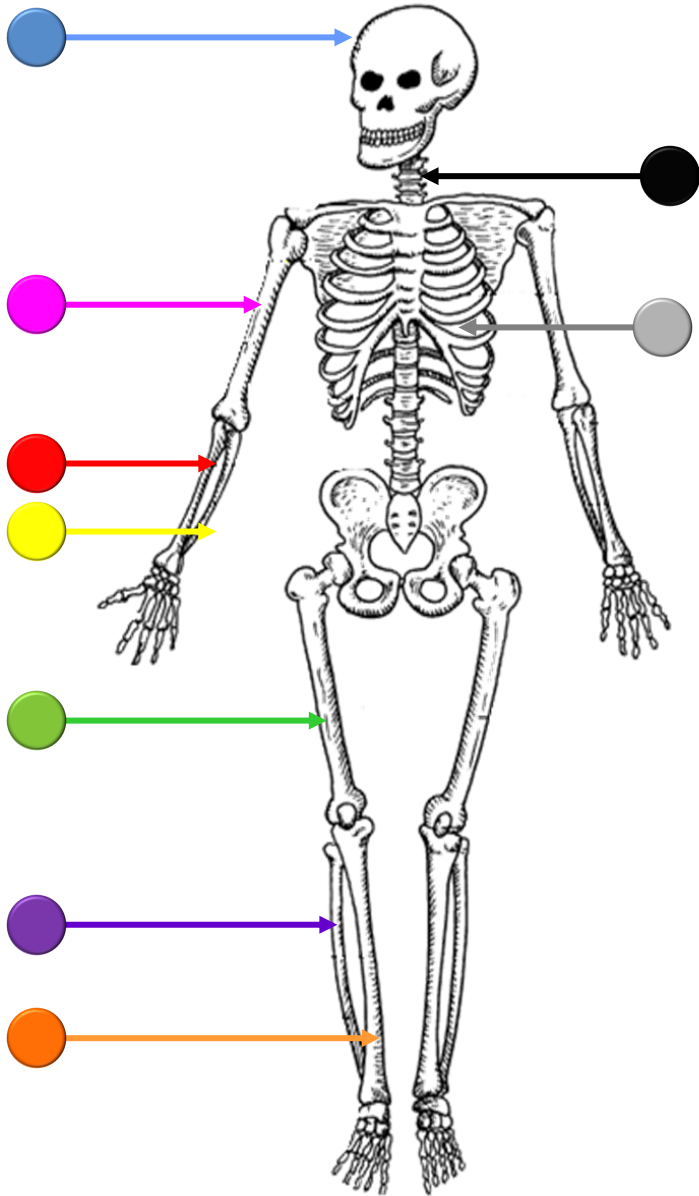


coude
phalanges
cou
hanche
poignet
cheville
genou
épaule







CARTAP | NCES

Sciences



crâne
péroné
humérus
cage thoracique
fémur
tibia
radius
colonne vertébrale
cubitus



CARTAP | NCES

Sciences